

© 2024 EDIZIONI MINERVA MEDICA  
 Online version at <https://www.minervamedica.it>  
 Italian Journal of Dermatology and Venereology 2024 mese;159(0):000-000  
 DOI: 10.23736/S2784-8671.24.07878-2

## First cases of contact injury following brown marmorated stink bug crush in Italy

*Halyomorpha halys* (Stål) (Heteroptera: Pentatomidae), the brown marmorated stink bug (BMSB), is a highly invasive insect species native to Asia (China, Taiwan, Korea, and Japan). *H. halys* belongs to the insect order Hemiptera (Rhynchotha), suborder Heteroptera and to the family Pentatomidae, which encompasses all stink bugs (or shield bugs).<sup>1</sup> In recent decades has emerged as a major insect pest of worldwide importance due to its invasiveness and polyphagy, causing significant agricultural losses, especially to orchard fruits, grapes, ornamental plants, vegetables, cereals etc. The first discovery in Europe occurred in Switzerland in 2004,<sup>2</sup> subsequently the species was found in the Italian region Liguria in 2007 and in Emilia Romagna region in the 2012 (first official record from Italy),<sup>3,4</sup> spreading in the following years throughout Italian regions. Herein, we report two illustrative cases of skin manifestations, due to contact with the BMSB. A 40-year-old Caucasian woman sought medical advice after swatting an insect on her volar surface of the right forearm, the insect was hidden into the cloths which were just collected from outside, where they were left to dry after washing. In the hours following the exposure, the subject complained itching associated with burning sensation and erythema at the site of contact. Skin manifestations are still present at the moment of the medical evaluation 48 hours after (Figure 1A). The patient was

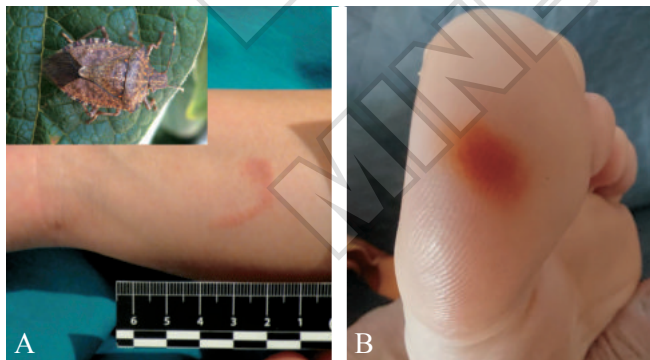


Figure 1.—A) Macular erythematous lesion in which a circular area can be identified where primary contact occurred and a trail compatible with the insect dragging, right forearm. B) Homogeneous brown-orange exogenous pigmentation involving both ridges and furrows, left foot.

treated with topical steroid and systemic antihistamines with improvement in five days; a slight post inflammatory hyperpigmentation persisted for weeks. The second case was a 59-year-old man who noticed an asymptomatic orange-to-brown macular lesion on the distal surface of the first toe of the left foot (Figure 1B). The patient hypothesized that the source of pigmentation was related to a stink bug, that he found stuck to the corresponding area of the sock. The event did not require any treatment and only clinical and dermatoscopic follow-up was carried out with resolution ad integrum within a few weeks. Both patients were resident in Italian regions Piedmont. It was possible to relate the skin lesions to secretions for defensive purposes produced by the insect, which were collected and kept in dry conditions. The entomological analysis of the specimens enabled to determine to be adults of *H. halys*. *H. halys* is a sap-sucking Heteroptera insect at all postembryonic stages that was recently introduced in Europe, where it has rapidly spread, creating serious problems for crops.<sup>4</sup> The species has thoracic and abdominal glands secreting chemicals with an antipredatory/disseminating action.<sup>5,6</sup> In *H. halys*, two aldehydes have been identified as major components of the secretions with repugnant/antipredatory functions.<sup>5-7</sup> The pathogenesis of the lesion could be traced back to the oxidation and reduction reaction of the aldehydes, which leads to the production of hydrogen ions (H+) that, on contact with tissues, cause chemical burns, as has also been hypothesized for contact keratitis following ocular exposure to *H. halys* body fluids.<sup>7</sup> Mild contact dermatitis has also been known to occur in fruit growers handling brown marmorated stink bug infested crops.<sup>8</sup>

Moreno DUTTO<sup>1</sup>, Edoardo CAMMARATA<sup>2\*</sup>,  
 Giuseppe LAURIA<sup>3</sup>, Andrea DRAGO<sup>4</sup>,  
 Elia ESPOSTO<sup>5</sup>, Paola SAVOIA<sup>6</sup>

<sup>1</sup>Emergency and Admission Department, Croce e Carle Hospital, Cuneo, Italy; <sup>2</sup>Clinic of Dermatology, SS. Antonio e Biagio e Cesare Arrigo Hospital, Alessandria, Italy; <sup>3</sup>Emergency Medicine and First Aid Section, Croce e Carle Hospital, Cuneo, Italy; <sup>4</sup>Entostudio S.r.l., Ponte San Nicolò, Padua, Italy; <sup>5</sup>SCDU Dermatology, University Hospital Maggiore Della Carità, Novara, Italy; <sup>6</sup>Department of Health Sciences, University of Eastern Piedmont, Novara, Italy

\*Corresponding author: Edoardo Cammarata, Dermatologic Clinic, SS. Antonio e Biagio e Cesare Arrigo Hospital, Via Venezia 16, I5121 Alessandria, Italy. E-mail: [edoardocammarata@gmail.com](mailto:edoardocammarata@gmail.com)

### References

1. Sparks ME, Bansal R, Benoit JB, Blackburn MB, Chao H, Chen M, et al. Brown marmorated stink bug, *Halyomorpha halys* (Stål), genome: putative underpinnings of polyphagy, insecticide resistance potential and biology of a top worldwide pest. *BMC Genomics* 2020;21:227.
2. Haye T, Garipey T, Hoelmer K, et al. Range expansion of the in-

vasive brown marmorated stinkbug, *Halyomorpha halys*: an increasing threat to field, fruit and vegetable crops worldwide. -. *J Pest Sci* 2015;88:665–73.

3. Maistrello L, Dioli P, Vaccari G, Nannini R, Bortolotti P, Caruso S, *et al.* First Records in Italy of the Asian Stinkbug *Halyomorpha halys*, a new Threat for Fruit Crops. *Giorn Fitopatol* 2012;1:283–8.

4. Cianferoni F, Graziani F, Dioli P. Review of the occurrence of *Halyomorpha halys* (Hemiptera: Heteroptera: Pentatomidae) in Italy, with an update of its European and World distribution. *Biologia* 2018;73:599–607.

5. Sagun S, Collins E, Martin C, Nolan EJ, Horzempa J. Alarm Odor Compounds of the Brown Marmorated Stink Bug Exhibit Antibacterial Activity. *J Pharmacogn Nat Prod* 2016;2:119.

6. Dettner K. Toxins, defensive compounds and drug from insects. In: Hoffmann KH, editor. *Insect molecular biology and ecology*. Boca Raton, FL: Taylor & Francis; 2015. p.39–43.

7. Shen YS, Hu CC. Irritant contact keratitis caused by the bodily fluids of a brown marmorated stink bug. *Taiwan J Ophthalmol* 2017;7:221–3.

8. Anderson BE, Miller JJ, Adams DR. Irritant contact dermatitis to the brown marmorated stink bug, *Halyomorpha halys*. *Dermatitis* 2012;23:170–2.

---

*Conflicts of interest*

The authors certify that there is no conflict of interest with any financial organization regarding the material discussed in the manuscript.

*Authors' contributions*

Moreno Dutto and Edoardo Cammarata equally contributed to the manuscript draft; all authors read and approved the final version of the manuscript.

*History*

Article first published online: \_\_\_\_\_, - Manuscript accepted: September 11, 2024. - Manuscript revised: June 26, 2024. - Manuscript received: January 19, 2024.

(Cite this article as: Dutto M, Cammarata E, Lauria G, Drago A, Esposto E, Savoia P. First cases of contact injury following brown marmorated stink bug crush in Italy. *Ital J Dermatol Venereol* 2024;159:000-000. DOI: 10.23736/S2784-8671.24.07878-2)

PROO  
MINERVA MEDICA